

*The Balkan Academy of Forensic Sciences (BAFS) Congress 2006.
Stara Zagora, Bulgaria, June 08, 2006.
Summary Book, pp:25.*



Case Report / Olgu Sunumu

The evaluation of a complex medico-legal case with syncope, diffuse subcutaneous emphysema, bilateral pneumothorax and eustachian valve

[Senkop, yaygın subkutan amfizem, bilateral pnömotoraks ve östakian valf bulunan karmaşık bir mediko-legal olgunun değerlendirilmesi]

Asirdizer M*., Yavuz MS*., Zeyfeoglu Y*., Tatlisumak E**.

(*) Department of Forensic Medicine, Celal Bayar University, Medical School, 45030, Manisa, Turkey.

(**) Department of Anatomy, Celal Bayar University, Medical School, 45030, Manisa, Turkey.

Abstract

One of the most important duties of a medical examiner is to define its cause when an injury occurred. An injury may occur due to violence e.g. child abuse, accidents e.g. home accidents, attempts to suicide e.g. jumping, or it may follow an illness. Even it may occur iatrogenically. The process of medico-legal diagnosis is not easy every time, especially if the victim is a child. The anamnesis and the observation of the behaviors of children and parents are very important but not always sufficient for diagnosis. The case submitted in this report is a nine years old male child. He was hospitalized in the State Hospital after fainted in the bathroom of his house. During the entrance of Manisa State Hospital, he was unconscious, his arterial blood pressure was 180/110 mmHg, his arterial pulsation rate was 180/minute, his respiration was shallow and there was a circular abrasion with 2 cm diameter on the right frontal region of his body. He was transported to Celal Bayar University Hospital after endotracheal intubation. Syncope, diffuse subcutaneous emphysema on his neck, thorax and abdomen and bilateral pneumothorax was diagnosed at University Hospital. Eustachian valve was detected at echocardiography. He was sent to Forensic Medicine Department of University Hospital for the preparation of his medico-legal report after he was discharged. In this report, we submitted the medico-legal evaluation of a case with eustachian valve, diffuse subcutaneous emphysema and bilateral pneumothorax and difficulties during medico-legal diagnosis as the major cause of the clinical aspects among trauma, illness, medical malpractice or complication.

Keywords:

Forensic medicine, medical malpractice, eustachian valve, pneumothorax and subcutaneous emphysema.

Özet

Bir yaralanma meydana geldiğinde onun nedeninin tanımlamak medikal araştırmaların en önemli görevlerinden biridir. Bir yaralanma çocuk istismarı gibi bir şiddet, ev kazarlı gibi bir kaza, yüksekten atlamalar gibi bir intihar teşebbüsüne bağlı olabileceği gibi o bir hastalığı da izleyebilir. Keza o iatrojenik olarak da meydana gelebilir. Mediko legal tanı gelişimi her zaman kolay değildir, özellikle çocuk bir kurbanda. Ananez ve çocuk ve ailesinin davranışlarının gözlenmesi çok önemli olsa da teşhis için daima yeterli değildir. Bu makalede sunulan olgu 9 yaşında bir erkek çocuktur. O evinin banyosunda bayıldıktan sonra Manisa Devlet Hastanesi' nde yatırılmıştır. Hastane girişinde, bilinçsiz, TA: 180/110 mmHg, nabız 180/dakika, solunumu yüzeysel olarak saptanmış ve sağ frontal bölgede 2 cm çaplı dairevi sıyrık tanınmıştır. Olgu endotrakeal entübasyon sonrasında Celal Bayar Üniversitesi Hastanesi' ne sevk edilmiştir. Üniversite hastanesi'nde senkop, boynunda, göğsünde ve karnında yaygın cilt altı amfizemi, bilateral pnömotoraks teşhis edilmiştir. Ekokardiografide Östakian Valf saptandı. Hasta taburcu edildikten sonra adli rapor düzenlenmek üzere Adli Tıp Anabilim dalı' na gönderildi. Bu makalede, biz östakian valf, yaygın cilt altı amfizemi ve bilateral pnömotorakslı bir olgunun mediko legal değerlendirilmesini ve travma, hastalık, medikal malpraktis veya komplikasyon arasındaki klinik görüşler arasından esas sebebin mediko legal tanısındaki zorlukları sunmaktayız.

Anahtar Kelimeler:

Adli tıp, medikal malpraktis, östakian valf, pnömotoraks ve cilt altı amfizemi.

1. Introduction

The procedure of the declaration and evaluation of medico-legal cases shows differences among states [1].

According to Turkish Penal Code (article: 280), every healthy person in Turkey may immediately inform every crime to judicial offices [2] and almost every types of

trauma is accepted as medico-legal case [3].

In present case, abrasion on the frontal region, syncope, diffuse subcutaneous emphysema, bilateral pneumothorax and eustachian valve was diagnosed and was announced to public prosecutor as judicial fact.

Public prosecutor requested the medico-legal report of the case from Forensic Medicine Department of Celal Bayar University.

The aim of this study is to define some procedures for appropriate approach for such complex cases.

2. Case

The case is submitted in this report is nine years old boy. He fainted after contraction of limbs at bathroom of his own house. In the entrance of Manisa State Hospital, he was unconscious, his arterial blood pressure was 180/110 mmHg, his arterial pulsation rate was 180/minute, breathing was shallow and there was 2 cm diameter abrasion on his right frontal region. He was transported to Hospital of Celal Bayar University by pre-diagnosis as "fall or suspicious epilepsy" after endotracheal intubation and intramuscular administration of 5 mg diazepam. In this hospital any radiological examination was not applied.

When the patient had arrived to Emergency Service of University Hospital, he was unconscious. His neurological findings were found as Glasgow Coma Scale was E1, M1, V (INTUBED), pupils were 4/4, pupil reflexes were -/-. The breath sounds at the left side was not present and at the right side it was decreased. There was peripheral cyanosis. The patient was consulted by Anesthesiology Clinic after hospitalization in Pediatric Surgery Clinic. In this consultation, asymmetric chest movements, the crepitating and diffuse subcutaneous emphysema on his neck, thorax and abdomen were determined. There was a 2 cm diameter abrasion on his right frontal region. His abdomen evaluated as normal in examination. The endotracheal tube was resettled to 18 cm because of the absence of ventilation of left lung in its 12 cm position and after the new settlement the ventilation of the lungs turned to normal bilaterally. In Pediatric Surgery Clinic, it was defined that there were bilateral pneumothorax and diffuse subcutaneous emphysema on his lateral x-ray of neck (figure-1), and PA radiograph of the chest (figure-2). Bilateral thoracic tubes were settled and underwater chest drainage was applied by using local anesthesia (figure-3). Bilateral inguinal subcutaneous emphysema was seen in the abdominal CT (figure-4). Level of blood glucose was 309 mg/dl, LDH was 364 U/l, CK/MB was 69.54 U/l, Urine density was 1.030, and other values of blood and urine analysis were normal. His consciousness was lost, Glasgow Coma Scale was found as E1, M5, V (INTUBED), his deep tendon reflexes were +/+, his pupil reflexes were +/+, and there were agitation and spontaneous actions during the neurosurgery consultation. In the cranial CT, bone fracture and intracranial lesion were not defined.

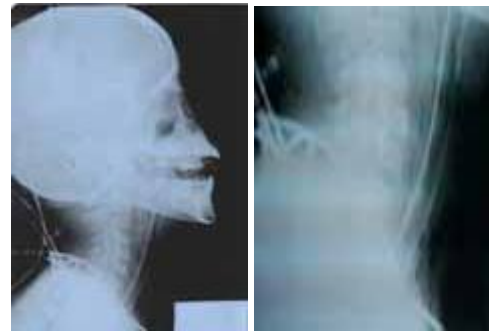


Fig. 1(a/b). Subcutaneous emphysema in front of neck in lateral cervical x-ray after intubation

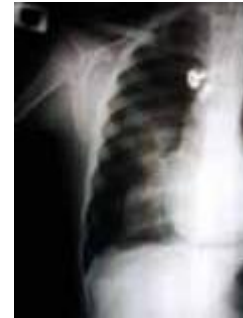

Fig. 2 (a/b). Bilateral pneumothorax and bilateral apical subcutaneous emphysema in PA radiograph of chest after intubation

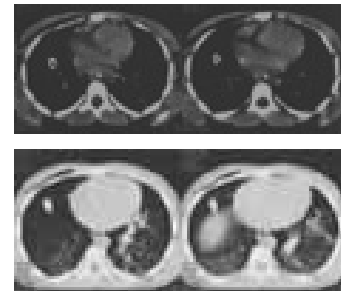


Fig. 3 (a-d). Right subcutaneous emphysema (at all scans) and left pneumothorax (at right upper scans) in thoracic CT after settling bilateral thoracic tubes



Fig. 4(a-b). Bilateral inguinal subcutaneous emphysema (at all scans) in abdominal CT

At following day of hospitalization, level of blood glucose as 102 mg/dl and CK/MB as 45.17 U/l were defined.

At fourth day of hospitalization, the reproduction of 10^3 staphylococcus aureus colonies sensitive to the most of the antibiotics was defined in cultures which obtained from endotracheal aspirates. However microbiological reproduction was not observed at cultures of blood and cerebro-spinal fluid.

At sixth day of hospitalization, level of blood glucose was 150 mg/dl. Pediatric Cardiology was invited for consultation because of the suspicion of incomplete right branch block in electrocardiography. Electrocardiogram was evaluated as normal by cardiologists and they claimed an echocardiographic examination.

At echocardiography of patient, the function of ventricles was determined as normal except mild pulmonary insufficiency. Patent ductus arteriosus or aorta coarctation was not defined. Eustachian valve was diagnosed at the right atrium, which might be the cause of syncope in the patient. Cardiologist even proposed that it could be the reason of stroke.

The thoracic tubes of patient were exerted at seventh day and the patient was discharged from hospital at twentieth day.

He was sent in the accompany of his grandfather (his father's dad) to Forensic Medicine Department of University Hospital for the preparation of his medico-legal report by public prosecutor after five month following to discharging from hospital.

In his medical biography obtained during this examination it was recorded that he was borned through normal vaginal way as 2800 g weight, 48 cm length at 37th pregnancy week. He had been hospitalized because of bronchiolitis at the 2nd month of life. He exhibited three times febrile convulsion between 1.5 and 2.5 years of age. He had been hospitalized because of pneumonia at the 3rd years of life. He was healthy between 3 and 9 years old. There was hypertension in his grandmother (his father's mom).

According to child's statements, his father was working in an office and his mother was a housewife. He had a 3 years old brother. He had been never beaten by his father but his mother sometimes had beaten him by her hands. When he fainted, his mother was at home but he was not defining any violence. He remembered that he went to bathroom, but he couldn't remember the following events.

According to his grandfather's statements, he had never witnessed and hadn't had any information about physical abuse of the child by his parents. His grandson was extremely healthy and he hadn't had any illness. In the day of the event, his grandson went to bathroom and he was found as fainted near of washbasin.

In the physical examination of child, his body growth was in the range of normal percentile. Any fresh traumatic lesion or sequel of an old traumatic lesion was not seen except scars related to thoracic tube application. In the systemic examination, any pathological finding was not identified. In the psychological examination, it was recorded that, he was easily cooperated, he hadn't had pessimistic behaviors and his answers hadn't had any contradiction despite cross questions of the specialists.

When the legal investigation documents were scrutinized

at Forensic Medicine Department, it was seen that there was not any contradiction between his father's and mother's statements. Additionally the examiners was not found a proof about trauma e.g. child abuse or intoxication e.g. carbon monoxide poisoning during scene investigation.

3. Discussion

Pneumomediastinum and subcutaneous emphysema generally occurs following trauma to the esophagus or lung [4]. It can be caused also by iatrogenic injury during surgery, endoscopy, or mechanical ventilation [5]. Tracheal perforation should be strongly suspected in cases of subcutaneous emphysema after tracheal intubation [6]. In particular, intubation by inexperienced personnel [7], difficult intubation [8], emergency intubation [9,10], and intubation with a double-lumen tube [11-14] may be associated with tracheal injury. Radiologic signs of tracheobronchial injury are nonspecific and include pneumomediastinum, pneumothorax, and progressive extrapulmonary soft-tissue air [15].

In the reported case, although presence or absence of tracheal injury was not pointed, the observation of the absence of pneumothorax or subcutaneous emphysema in the PA radiographs of chest before endotracheal intubation, the presence of these pathologies in the PA radiographs of chest, and thoracic and abdominal CTs after the application of endotracheal tube was implying the role of endotracheal tube in the occurrence of pneumothorax and subcutaneous emphysema. Additionally the events occurred with the change of settlement of the endotracheal tube at University Hospital was supporting the idea that those pathologies were related to the endotracheal intubation.

Asirdizer M and Tatlisumak E defined that, eustachian valve may be cause of sudden death when syncope, stroke, fat embolism, gas embolism accompanied to it even eustachian valve can not be a cause of death alone [16]. In some other studies, it was defined that, eustachian valve or ridge which as one of right atrial endocardial structures was proven to support the atrial flutter reentrant circuit [17-19].

In the present case; the result of echocardiography revealed that the eustachian valve diagnosed as an embryological remnant at the right atrium of the heart might had been the cause of syncope in the patient. In the clinical, radiological and laboratory examination of child, any traumatic lesion was not defined except the existence of a 2 cm diameter abrasion on his right frontal region. There was not any pathology which could explain syncope except eustachian valve.

In medico-legal evaluation of the case, it was decided that the head of the child had been injured by knocking to the washbasin in bathroom during syncope due to eustachian valve. The emergency endotracheal intubation had been applied as soon as he had been transported to hospital. In final stage of this evaluation,

forensic examiners decided that bilateral pneumothorax and diffuse subcutaneous emphysema was caused due to medical malpractice resulted from misplacement of endotracheal intubation because after changing the location of the endotracheal tube lung ventilation returned to normal. The growing bilateral pneumothorax and diffuse subcutaneous emphysema were not accepted as an expected complication during applying endotracheal intubation after investigation of literature on this subject.

This case report was submitted as an example for emphasizing the importance of the detailed medico-legal evaluation for analysis in the similar complex cases.

References

1. Knight B. *Simpson's Forensic Medicine*. 10th Edition. Edward Arnold Press, 1997, London: 8-11.
2. Ozgenç I. *Explanatory Turkish Penal Codes*. Seckin Publishing House, 2004, Ankara: 391. (Turkish Publication)
3. Bilge Y, Gundogmus ÜN, Gunduz T, Hanci IH, Katkici U, Kok AN, Yavuz IC, Istanbul Chambers of Doctors. *Legal Responsibility of Medical Doctors in Forensic Medicine for First Step* (Edited by Istanbul Chambers of Practitioners & Association of Forensic Medicine Specialists). Turkish Medical Association Press, 1999, Ankara: 5-8. (Turkish Publication)
4. Na SJ, Lee SI, Chung TS, Choi YC, Lee KY. *Pneumomediastinum due to intractable hiccup as the presenting symptom of multiple sclerosis*. *Yonsei Med J*. 2005 Apr 30;46(2):292-5 (Abstract).
5. Cavuslu S, Oncul O, Gungor A, Kizilkaya E, Candan H. *A case of recurrent subcutaneous emphysema as a complication of endotracheal intubation*. *Ear, Nose & Throat Journal*, 2004 Jul;83(7): 485-8.
6. Kaneko Y, Nakazawa K, Yokoyama K, Ishikawa S, Uchida T, Takahashi M, Tsunoda A, Makita K. *Subcutaneous emphysema and pneumomediastinum after translaryngeal intubation: tracheal perforation due to unsuccessful fiberoptic tracheal intubation*. *J Clin Anesth*. 2006 Mar;18(2):135-7.
7. Stewart RD, Paris PM, Winter PM, Pelton GH, Cannon GM. *Field endotracheal intubation by paramedical personnel. Success rates and complications*. *Chest* 1984;85:341-5.
8. Chortkoff BS, Perlman B, Cohen NH. *Delayed pneumothorax following difficult tracheal intubation*. *Anesthesiology* 1992;77: 1225-7.
9. Taryle DA, Chandler JE, Good Jr JT, Potts DE, Sahn SA. *Emergency room intubations—complications and survival*. *Chest* 1979;75:541-3.
10. Evagelopoulos N, Tossios P, Wanke W, Krian A. *Tracheobronchial rupture after emergency intubation*. *Thorac Cardiovasc Surg* 1999; 47:395-7.
11. Kaloud H, Smolle-Juettner F, Prause G, List W. *Iatrogenic ruptures of the tracheobronchial tree*. *Chest* 1997;112:774 - 8.
12. Hoffman HS, Rettig G, Radke J, Neef H, Silber RE. *Iatrogenic ruptures of the tracheobronchial tree*. *Eur J Cardiothorac Surg* 2002; 21:649 - 52.
13. Borasio P, Francesco A, Chiampo G. *Post-intubation tracheal rupture: a report on ten cases*. *Eur J Cardiothorac Surg* 1997;12:98 - 100.
14. Sivalingam P, Tio R. *Tension pneumothorax, pneumomediastinum, pneumoperitoneum, and subcutaneous emphysema in a 15-year-old Chinese girl after a double-lumen tube intubation and one-lung ventilation*. *J Cardiothorac Vasc Anesth* 1999;13:312-5.
15. Chen JD, Shanmuganathan K, Mirvis SE, Killeen KL, Dutton RP. *Using CT to diagnose tracheal rupture*. *AJR Am J Roentgenol*. 2001 May;176(5):1273-80.
16. Asirdizer M., Tatlisumak E. *The role of eustachian valve and patent foramen ovale in sudden death*. *J Clin Forensic Med*. 2006 Jan 24; [Epub ahead of print]
17. Olgin JE, Kalman JM, Fitzpatrick AP, Lesh MD. *Role of right atrial endocardial structures as barriers to conduction during human type I atrial flutter: activation and entrainment mapping guided by intracardiac echocardiography*. *Circulation*. 1995; 92(7):1839-48.
18. Nakagawa H, Lazzara R, Khastgir T, Beckman KJ, McClelland JH, Imai S, Pitha JV, Becker AE, Arruda M, Gonzales MD, Widman LE, Rome M, Neuhauser J, Wang X, Calame JD, Goudeau MD, Jackman WM. *Role of the tricuspid annulus and the eustachian valve/ridge on atrial flutter: relevance to catheter ablation of the septal isthmus and a new technique for rapid identification of ablation success*. *Circulation*. 1996; 94(3):407-24.
19. Obel OA, Camm AJ. *Supraventricular tachycardia. ECG diagnosis and anatomy*. *Eur Heart J*. 1998;19 Suppl E:E13-24, E50-1.